

Repurposing medical devices as “button” esophagostomy tubes for extended nutritional support

Melanie D. Craven 

Western College of Veterinary Medicine, 52
Campus Dr., Saskatoon, Saskatchewan, S7N
5B4, Canada

Correspondence

Melanie D. Craven, Western College of
Veterinary Medicine, 52 Campus Dr,
Saskatoon, SK, Canada. S7N 5B4
Email: melaniecraven@gmail.com

Abstract

Background: Esophagostomy tubes (E-tubes) are widely utilized for extended nutritional support in dogs and cats. Problems associated with their use include the unwieldy excess (10–20 cm) of external tubing, constant need for neck wraps and necessity for skin sutures, suture tract infection, and tube loss if sutures fail.

Objectives: To evaluate 2 different, low profile (LP) “button” products intended for use in people as enteral (jejunostomy [J] and gastrojejunostomy [G-J]) feeding tubes for suitability as LP E-tubes in dogs and cats.

Animals: A young giant breed dog that required extended (>6 months) nutritional and fluid support during recovery from severe neurological illness with protracted adipsia, anorexia, and dysphagia.

Methods: Prospective evaluation of 2 commercially available LP feeding devices after placement of a standard E-tube. An LP J-tube and an LP G-J tube were assessed in consecutive 4-week trials, for tube retention, patient comfort, stoma health, and functionality.

Results: Both products performed extremely and equally well as LP E-tubes in this clinical patient, enhancing patient freedom and comfort by eliminating external tubing, skin sutures, and bandaging. The dual port G-J tube allows medication delivery (eg, sucralfate) to the entire esophagus, but for safety alone (ie, to avoid aspiration), the single port J-tube appears the best device for client-owned patients.

Conclusions and Clinical Importance: The LP enteral feeding tubes from the human medical field can be successfully used as LP E-tubes in dogs and cats, offering superior patient comfort, with no obvious detriment to the patient and main drawback of higher cost.

KEYWORDS

button, esophagostomy, E-tube, feeding tube, low profile

Abbreviations: AMT, Applied Medical Technologies; EMLA, eutectic mixture of local anesthetics; E-tube, esophagostomy tube; G, gastric; G-J, gastrojejunostomy; G-tube, gastrostomy tube; J, jejunostomy; LP, low profile.

This is an open access article under the terms of the Creative Commons Attribution-NonCommercial-NoDerivs License, which permits use and distribution in any medium, provided the original work is properly cited, the use is non-commercial and no modifications or adaptations are made.

© 2021 The Author. *Journal of Veterinary Internal Medicine* published by Wiley Periodicals LLC on behalf of American College of Veterinary Internal Medicine.

1 | INTRODUCTION

Nutrition is essential for cellular repair during recovery from illness in dogs and cats,^{1,2} consistent with the finding that energy supply is strongly associated with hospital discharge.³ Companion animals with poor appetite often undergo feeding tube placement, using nasogastric tubes in the short term (<7 days) and esophagostomy or gastrostomy tubes for longer term support^{1,4} (E-tube median duration, 19 days⁵; G-tube, 76 days⁶). In people, standard G-tubes often are replaced by low profile (LP) style devices after the stoma has formed.⁷ These devices also can work well for dogs and cats,⁸ where it is particularly important for interventions to interfere minimally with natural behavior and activities. By eliminating the (not insubstantial) problems inherent with standard feeding tubes, such as bulky external tubing, constant need for skin sutures and body wraps, LP tubes allow more safety, freedom, and activity. So far, no reports have described the use of a LP esophagostomy tube in any species.

In recent years, new feeding tubes have been developed for use in people, including LP jejunostomy (J) and gastrojejunostomy (G-J) tubes.^{9,10} The long length and multiple ports of these tubes favor their utilization as LP esophagostomy tubes in dogs and cats. The safety

profile of an LP E-tube offers advantages over an LP G-tube. The risks of G-tubes in all patients can be substantial if the tube leaks, causing septic peritonitis and death, whereas a dislodged E-tube will usually cause no, or only minor complications (eg, localized cellulitis).¹¹⁻¹³ Veterinary patients naturally are associated with higher risk because they often try to remove these tubes, and may be more physically active than desirable.

The principal hypothesis of our study was that LP tubes intended for enteral feeding in people could be safely and successfully utilized as an LP E-tube in a dog. The objective was to test 2 widely available products designed for humans in a dog that required extended nutritional support, with respect to the following variables: longevity of tube retention, stoma health, patient acceptance, and tube functionality.

2 | MATERIALS AND METHODS

2.1 | Animals and study design

A 3.5-year-old male Great Dane undergoing treatment for meningoencephalomyelitis had undergone placement of an E-tube

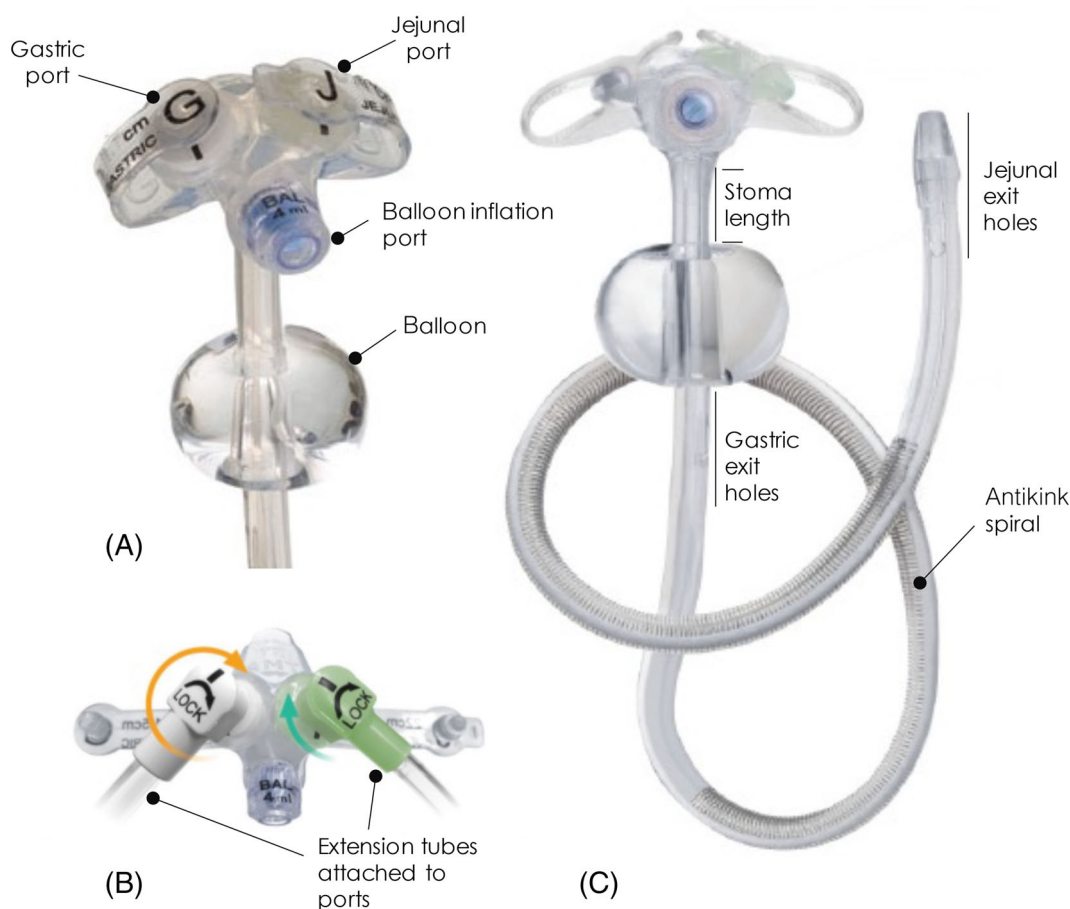


FIGURE 1 AMT G-Jet gastrojejunostomy tube. (A) Dual ports, G (gastric) and J (jejunostomy) with balloon inflation port (blue). (B) With extension tubes attached to each port; the extension tubes are not interchangeable. (C) 45 cm length tube showing spiral antikink technology and exit holes immediately below the balloon for the G-port

4 weeks earlier for nutritional support. A standard 18 Fr silicone E-tube had been placed without complication and secured with skin sutures. Mild complications had occurred around the suture sites, with suture tract inflammation and mild skin infection, and an Elizabethan collar was required to protect the tube. After 4 weeks, the E-tube still was required for a further indeterminant period, and therefore trials were undertaken with 2 products designed for the human medical field, an LP G-J (Applied Medical Technologies, AMT G-Jet tube, Figure 1) and an LP J-tube (Kimberley Clark/Avanos Medical Mic-Key LP J-tube, Figure 2). In consecutive trials of 4 weeks each, tubes were evaluated for tube retention, stoma health, patient acceptance, and tube functionality by the same veterinarian owner (with experience of managing standard and LP feeding tubes). The same diet was used for each trial, prepared by presoaking dried kibble with warm water and blending to a consistency that could be fed by tube.

2.2 | Tube placement procedure

To replace the standard E-tube with the first LP tube (AMT G-Jet), a local anesthetic cream (EMLA 5%, AstraZeneca) was applied to the stoma site and the dog was sedated IV (butorphanol 0.2 mg/kg, dexmedetomidine 250 µg/m², midazolam 0.5 mg/kg). The stoma had been measured (Figure 3) and a tube for stoma length of 5.0 cm was used. Before placement, the balloon was checked for leaks by inflation with sterile water and then fully deflated. The stoma site was cleaned using sterile swabs and chlorhexidine, and sterile gloves were worn. An atraumatic, blunt-ended 1.0 mm guidewire was inserted into the standard E-tube, and the E-tube was removed over the top, leaving

the guidewire in place. The empty stoma was gently cleaned using sterile cotton swabs and chlorhexidine. A guidewire adapter (supplied) was inserted into the J-port (AMT G-Jet) and the G-port (Mic-Key), and the end of the tube was inserted over the guidewire, into the stoma. These tubes have 1-way antireflux valves, and the guidewire is used via the supplied adapter to avoid damaging the valve. Copious sterile lubrication and gentle but firm pressure with a rotatory motion were applied to introduce the new tube. The balloon was inflated with 2.5 mL of sterile water and a barrier cream (Sudocrem, TEVA UK Ltd) was applied, as well as a light neck wrap.

Replacement of the LP G-J tube with the LP J-tube involved firstly deflating the balloon completely, by depressing the blue valve using a syringe and aspirating the fluid. Sometimes the valve can stick, and a microscrowdriver may be inserted into the blue balloon valve to depress and turn the valve, to release the water (the tube cannot be removed until it is fully deflated to avoid damage to the stoma). The remainder of the procedure follows as described above.

2.3 | Tubes

The LP G-J tube by Applied Medical ("AMT G-Jet") is a medical-grade silicone, LP balloon-style tube with 2 ports: the G-port, which exits to the stomach and is used for delivering medication, draining excess fluids, or venting air and the J-port, that exits to the jejunum and is used to deliver nutrition. Feeding is accomplished by attaching an extension set to the "button" and to avoid using the wrong port, each has its own locking extension set. For use as an E-tube, only the J-port can be safely used for feeding because the G-port is too close to the

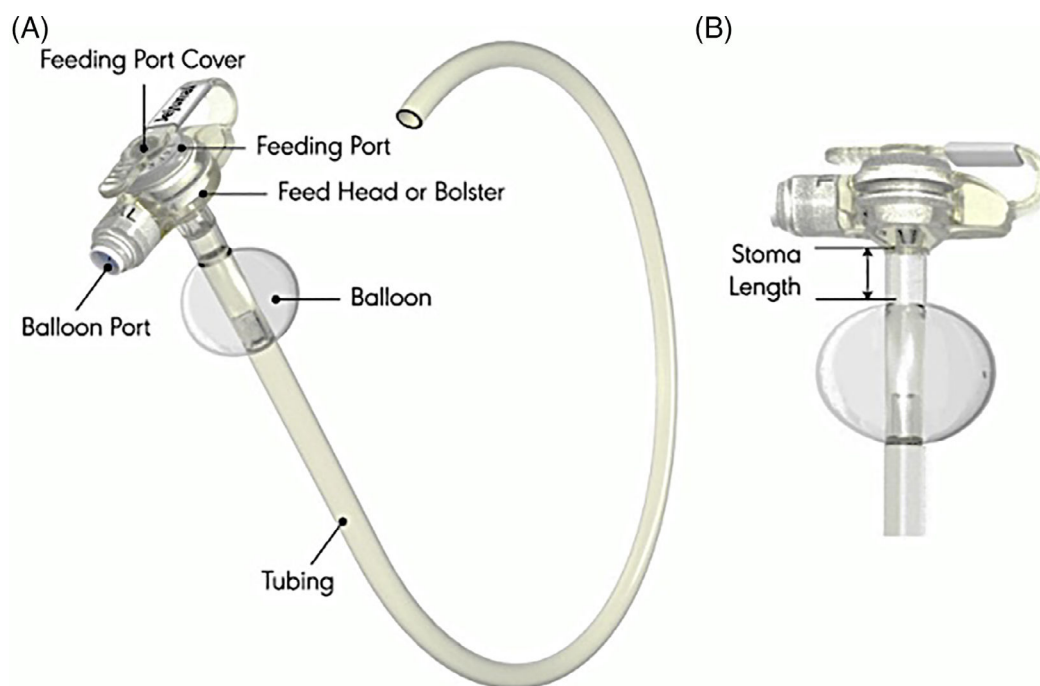


FIGURE 2 Mic Key low profile jejunostomy tube. (A) Single port tube with one exit hole at the end of the tube. The "button" is smaller than the AMT G-Jet in Figure 1. (B) Stoma length is measured from the ventral surface of the button to the top of the balloon



FIGURE 3 Stoma measuring device (Applied Medical Technologies). The tube is introduced into the stoma, and the balloon is inflated and gently pulled until slight resistance is felt. The stoma length can then be measured

pharynx and could result in aspiration, but it can be used to administer liquid sucralfate. An antireflux valve in the G- and J-ports prevents backflow during feeding. The G-Jet is produced in 14, 16, and 18 Fr sizes with stoma lengths ranging from 1 to 6 cm and jejunal length from 15 to 45 cm (Table 1). The “button” on this device has small “feet,” allowing the skin around the stoma to stay dry and open to the air which can help to prevent infection. Antikink technology is incorporated, with a lightweight spiral of metallic wire in the wall of the tube. The “Mic Key” LP J-tube (Kimberley Clark/Avanos Medical) is a medical-grade, balloon-style silicone tube with a jejunal port that has an antireflux valve. It is produced in 14 and 18 Fr sizes, for stoma lengths from 0.8 to 4.5 cm and supplied in a standard tube length of 51 cm, to be cut to requirements before use. For feeding, a Mic Key-specific extension set is attached to the “button.” The extension sets for both tube types can be reused if cleaned after each use.

2.4 | Tube evaluation

During each 4 week trial, the tube site was inspected visually and the peri-stomal area and cervical soft tissues were palpated 4 times daily for evidence of swelling, redness, discomfort, discharge. The stoma

was cleaned using a povidone iodine swab after each meal, and a barrier cream was applied. A neoprene, Velcro-secured circumferential neck wrap was used for the first week, until it appeared that balloon retention was effective, and a clean wrap was applied daily. Gentle pressure was applied to the tube once daily to ensure that the balloon remained inflated, and the balloon was emptied and refilled once weekly to check for balloon leaks. The patient's demeanor, activity, and willingness to allow tube and stoma handling were noted.

3 | RESULTS

3.1 | The AMT LP G-J tube as an esophagostomy tube

The G-Jet tube (Figure 1) was the softest and most flexible, and appeared to offer most patient comfort. The design of the “button” allows for airflow to the stoma, seems very comfortable, and is easy to clean. The patient's stoma site became noticeably healthier within 7 to 10 days of tube change, with an overall decrease in tract and peri-stomal skin redness, and decreased stoma leakage (as the stoma closed around the tube). The mildly infected suture tracts present

TABLE 1 Available low profile tubes for esophagostomy feeding

Tube	Available sizes	Stoma lengths	Comment	Cost (USD)
AMT G-Jet gastrojejunostomy balloon button ^a	14, 16, and 18 Fr Length: 15-45 cm	1-6 cm	Antikink technology Dual ports Most flexible tube	\$750
AMT Micro G-Jet Pediatric gastrojejunostomy balloon button ^a	14 Fr Length: 10-22 cm	0.8-1.7 cm	Upper tube (stoma) 14 Fr Jejunal tube 8 Fr Not trialed	\$650
Mic Key jejunostomy balloon button ^b	14 and 18 Fr Adjustable length: 51 cm	0.8-4.5 cm	Single port Easiest to place	\$350
Mic Key gastrojejunostomy balloon button ^b	14, 16, 18, and 22 Fr Length: 15-45 cm	1-7 cm	Not trialed Has the most prominent “button”	\$700

^aBy Applied Medical Technologies (AMT).

^bBy Kimberley Clark/Avanos Medical.

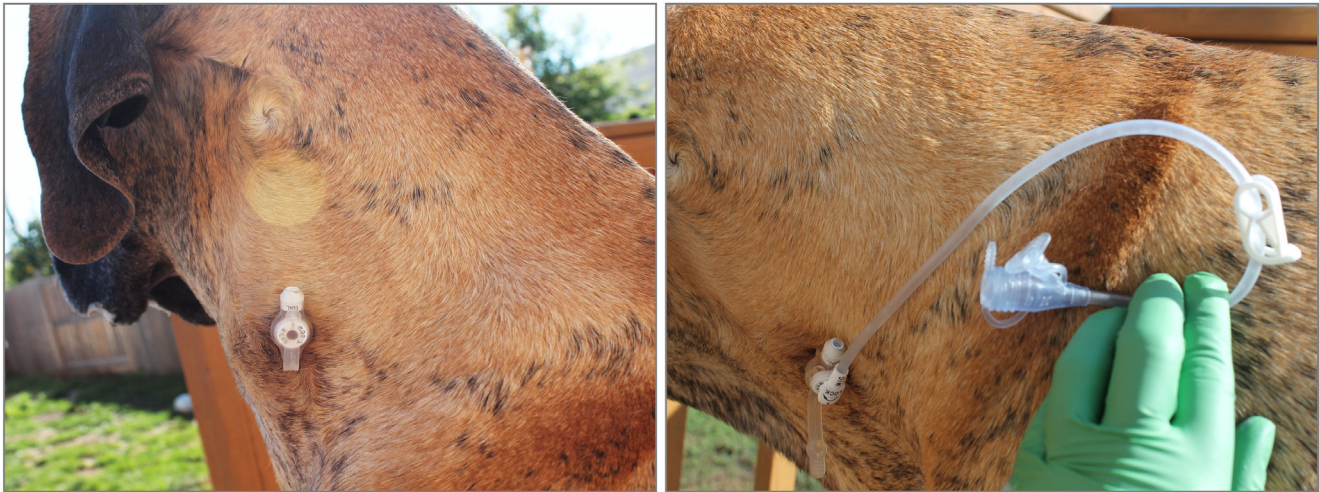

FIGURE 4 Mic-Key LP “button” J tube (left) and with locking extension tubing attached (right)

after suture removal healed within approximately 10 days. The tube tip is slightly bulkier than the rest of the tube, and because of its flexibility this tube was more difficult to place. The tube's flexibility derives in part from antikink technology, which resembles a metal “slinky” spring in the wall of the tube, and may prove useful in decreasing the frequency of tube displacement. Regarding functionality, the G-port and extension were very easy to use for administering liquid sucralfate to the esophageal mucosa. The J-port and extension also were used with ease for feeding liquified kibble of the same consistency as used with the standard E-tube. The ports were difficult to confuse because they each have a different extension set that will not fit the other port. This tube did not appear to become discolored or degrade during the 4-week trial and potentially could have been used for a longer time period. The button system appeared overall to be easier to use than the standard E-tube because, subjectively, it caused less disturbance to the dog and had a 30 cm extension set so that syringe reloading, connection and disconnection could be accomplished more easily. Subjectively, the dog showed greater acceptance of this intervention compared to the standard E-tube and did not try to remove the tube. An Elizabethan collar was not required. The only disadvantage was the high cost, of approximately \$750 USD.

3.2 | The Mic Key LP J tube as an esophagostomy tube

The Mic Key J-tube (Figures 2 and 4) was less expensive, approximately \$350 USD. The silicone tube is very soft but less flexible, owing perhaps to the absence of antikink technology. It is supplied at a standard length of 51 cm and is cut to the required length. Tube placement was uncomplicated and slightly easier because the tube is less flexible. The “button” is smaller than that of the AMT G-Jet and less conspicuous because it does not have the “feet” of the G-Jet tube. The feeding extension was easy to attach and use (Figure 4), but medicating the upper esophagus was not possible because there is

TABLE 2 General stoma and tube care

Low profile E-tube maintenance
When handling the tube, stoma, and extension sets, first wash hands and always wear gloves
Inspect the stoma site for redness, discharge, swelling, odor twice daily
After each meal, clean stoma gently without pulling on tube, using gauze and an antiseptic solution (eg, diluted chlorhexidine, povidone-iodine, hydrogen peroxide 3%)
Apply barrier cream for example, sudocrem, zincofax after cleaning
If a neck wrap is not used, do not allow animal to lay on the tube side on a dirty surface
Avoid swimming and beaches (sand in stoma)
Protect stoma with a neck wrap during vigorous play
Observe patient for signs of a tube problem such as gagging, regurgitation or dysphagia, inappetence, which may indicate a more serious problem such as esophagitis or fungal (eg, <i>Candida</i> spp.) infection
Weekly, deflate and reinflate the balloon to check for leaks
Weekly, apply antifungal product to stoma as a preventive measure for example, clotrimazole
Monthly, culture from the stoma site and check the need for tube replacement and reorder tube

only a J-port. The same tube was used throughout the 4-week trial with no obvious degradation or discoloration, and the patient's acceptance, comfort and tube functionality were equivalent to the AMT G-Jet. The stoma site appeared comparably healthy, without redness or discharge and minimal leakage. At the end of the 4-week trial, this tube continued to be used for a total of 4 months.

Both products were used successfully as LP E-tubes for this clinical patient and compared to the standard E-tube, the appearance of the stoma was healthier with both LP tubes. The AMT G-Jet was subjectively preferred by the author for its design features, including the

TABLE 3 Some common tube problems, possible solutions and prevention

Problem	Possible cause	Action	Prevention
Patient is gagging	Esophagitis	Treat esophagitis (sucralfate, omeprazole)	Check tube care and feeding regime
	Stoma infection (bacterial/fungal)	Culture from stoma, treat infection as required	Clean or replace tube more often
	Tube, antiseptic or other topical preparation allergy	Replace tube	Consider history of allergy
Patient constantly tries to remove tube	Stoma infection (bacterial/fungal)	Culture from stoma, (bacterial and fungal) and treat infection	Check cleaning regime and home hygiene
	Possible reaction to tube material or wrap	Use a different wrap and tube make or remove tube	Consider history of allergy
	Allergy to topical antiseptic or barrier cream	Change cleaning products	
Discharge from stoma	Stoma infection, bacterial/fungal	Culture stoma site, treat infection	Check cleaning regime and home hygiene
	Tube is incorrect size	Remeasure and replace tube with correct size	Replace tube on time
Food material coming from stoma	Tube is too small	Replace tube with appropriate size	Replace tube on time
	Stoma infection (bacterial/fungal)	Culture stoma site, treat infection	Check cleaning regime and home hygiene Use barrier cream with an ostomy pad
Tube blocked	Tube kinked (uncommon)	Remove and inspect or replace tube	Antikink tubing (AMT G-Jet)
	Food obstruction	Clear obstruction using a tube cleaning brush	Use appropriate diet and water flush after feeding
Tube becomes discolored or material is distorted	Discoloration by topical agents for example, iodine	No action if tube is normally functional	Use optimal cleaning regime
	Tube material is degraded	Inspect and/or replace tube	Replace tube on time
	Tube is infected for example, fungal infection	Culture from stoma (bacterial and fungal)	Prophylactic application of topical antifungal
Button cap is frequently found to be open	Defective or old tube	Replace tube as soon as possible	Prevent gastric dilatation by taping cap closed and use neck wrap

button's "feet" and greater tube flexibility, perhaps offering greater comfort. The balloon of the Mic Key tube however, appeared subjectively slightly more robust and the single port also eliminates potential feeding errors by the owner.

4 | DISCUSSION

Low profile "button" style feeding tubes have been used in veterinary patients for many years as G-tubes.^{6,8,14,15} This report provides the first description of the extended use of an LP esophagostomy tube in a clinical patient. The products evaluated are designed for pediatric or adult use and are available in many sizes that would likely accommodate all breeds of dogs and cats (Table 1). Both products evaluated here were found to be preferable to the standard E-tube with regard to patient comfort and stoma health, potentially implicating factors such as skin sutures and external tube length in stoma complications. Perhaps the most important outcome observed is that by eliminating the external tubing, bandaging and skin sutures, the invasiveness of

the E-tube was decreased, favorably impacting the dog's return to natural behavior. Animals typically are less accepting of medical interventions, and this type of device may prove to be particularly useful. It would be possible to place either product in a 1-step procedure, without risk of tissue compromise or tube dislodgement caused by stoma swelling, as has been reported with 1-step G-tubes.¹⁶

E-tubes have been associated with stoma infection in 33.7% and 31.5% of cases in 2 recent studies.^{5,17} In this clinical patient, the stoma's appearance improved with the LP E-tube compared to the standard E-tube. The skin sutures that secured the standard E-tube caused swelling, redness, and skin tracts. The LP tubes eliminate the need for skin sutures, which would be anticipated to decrease infection rates. Another reason for improved stoma health was the observed decreased leak of esophageal content. The tube mobility associated with an excess of external tube length is thought to cause stoma enlargement and more leakage from the tube, with resultant risk of inflammation and infection.¹⁸ An important difference of the "button," compared to standard E-tubes, is that greater handling of the tube is required at the stoma for attaching the extension

set, which necessitates careful tube management (Table 2), including the use of gloves to avoid infection.

Dislodgement has been reported as a complication of standard E-tubes in 8%¹⁷ and 12.4%⁵ of cases, because of suture failure, removal by the patient or both. Because the LP button is small and flush with the skin, there is less risk of dislodgement by the patient. Although suture failure is eliminated, balloon leak or rupture can cause failure of LP tubes and seems to be the most common reason for tube failure, reported in 61% of patients in a study of 84 children.¹⁹ Notably, these balloons were situated in the acidic gastric lumen and their mean longevity was still quite long (6 months). The nonacidic esophageal lumen would be expected to cause less balloon degradation, but also of note is that tube replacement every 3 to 4 months generally is recommended by the manufacturer. In dogs, there may be higher risk of balloon puncture and tube loss if hard chewsticks or bones are fed. For emergency replacement when the tube is completely dislodged, for the purpose of maintaining an open stoma (and not for feeding or medication administration), owners could be shown how to place a Foley balloon tube in the stoma before travel to the veterinary clinic.

The products evaluated here were used as replacement tubes, after the stoma had fully formed, but it also would be possible to apply either product in a 1-step procedure. The attractiveness of 1-step LP G-tubes is that they eliminate the problem of excess tubing and bandaging much sooner, without having to wait 4 to 6 weeks for the stoma to fully form. However, when the stoma experiences post-operative swelling, there is risk of dislodgement because of migration of the tube intra-abdominally.^{8,14,15,20} A very high rate of dislodgement (38% of cases), was reported in a study of 1-step G-tubes in colony cats.¹⁶ In the esophagus, the prospect of a 1-step tube does not entail the risks associated with 1-step G-tubes (ie, tube migration, pressure necrosis, septic peritonitis). The adverse effects of E-tube loss are relatively minor, (eg, cellulitis, local infection) and as such it would be possible to use the products evaluated here as 1-step LP E-tubes. Necessary minor modifications to the placement procedure involve delaying balloon inflation until after the stoma has formed to prevent unnecessary pressure, pain, and tissue damage as the stoma swells. For the first 10 to 14 days, the tube should be secured with skin sutures that must never be placed circumferentially around the tube itself (because the balloon inflation valve could be damaged), but rather can be applied over the top of the “button” in a figure 8 pattern, either directly or using butterfly tapes. When wound swelling has resolved, the retention balloon is inflated with sterile water and skin sutures are no longer necessary. The disadvantage here is that stoma length cannot be measured beforehand and must be estimated. Suggested stoma length for 1-step placement in cats is 2.0 to 3.0 cm and in dogs, 4.5 cm (>40 kg), 4 cm (20–40 kg), and 3.5 cm (<20 kg); the 82 kg dog of this report had a mature stoma length of 4.0 cm. Overestimation is always safer and more comfortable than underestimation, and the impact of gravity on the water-filled balloon tends to retain it in the esophagus, minimizing the exposure of any redundant tubing.

The main disadvantage is cost, which would be prohibitive in some cases compared to the cost of a standard E-tube at approximately \$50 to \$100 USD. Nevertheless, the potential quality of life

benefit and stoma health advantage are considerable when these tubes are utilized for prolonged time periods. For safety considerations alone, and unless esophagitis is present that necessitates prolonged treatment, the single port Mic Key J-tube is recommended. Optimizing tube care (Table 3) may enhance longevity and avoid potential complications, but future studies with a larger patient number will better inform the questions of tube longevity and complication rates.

ACKNOWLEDGMENT

No funding was received for this study.

CONFLICT OF INTEREST DECLARATION

Authors declare no conflict of interest.

OFF-LABEL ANTIMICROBIAL DECLARATION

Authors declare no off-label use of antimicrobials.

INSTITUTIONAL ANIMAL CARE AND USE COMMITTEE (IACUC) OR OTHER APPROVAL DECLARATION

Authors declare no IACUC or other approval was needed.

HUMAN ETHICS APPROVAL DECLARATION

Authors declare human ethics approval was not needed for this study.

ORCID

Melanie D. Craven  <https://orcid.org/0000-0002-1759-0778>

REFERENCES

1. Chan DL. Nutritional support of the critically ill small animal patient. *Vet Clin N Am Small Anim Pract.* 2020;50:1411-1422.
2. Sharma K, Mogensen KM, Robinson MK. Pathophysiology of critical illness and role of nutrition. *Nutr Clin Pract.* 2019;34:12-22.
3. Brunetto MA, Gomes MOS, Andre MR, et al. Effects of nutritional support on hospital outcome in dogs and cats. *J Vet Emerg Crit Care.* 2010;20:224-231.
4. Han E. Esophageal and gastric feeding tubes in ICU patients. *Clin Tech Small Anim Pract.* 2004;19:22-31.
5. Nathanson O, Mcgonigle K, Michel K, Stefanovski D, Clarke D. Esophagostomy tube complications in dogs and cats: retrospective review of 225 cases. *J Vet Intern Med.* 2019;33(5):2014-2019. doi: 10.1111/jvim.15563
6. Yoshimoto SK, Marks SL, Struble AL, Riel DL. Owner experiences and complications with home use of a replacement low profile gastrostomy device for long-term enteral feeding in dogs. *Can Vet J.* 2006;47:144-150.
7. Koulentaki M, Reynolds N, Steinke D, et al. Eight years' experience of gastrostomy tube management. *Endoscopy.* 2002;34:941-945.
8. Elliott DA, Riel DL, Rogers QR. Complications and outcomes associated with use of gastrostomy tubes for nutritional management of dogs with renal failure: 56 cases (1994-1999). *J Am Vet Med Assoc.* 2000;217:1337-1342.
9. Moslim MA, Falk GA, Seifarth FG. Novel modified Seldinger technique for gastrojejunal feeding tube placement. *JSLs.* 2018;22:e2017.00091. doi:10.4293/JSLs.2017.00091
10. Michaud L, Robert-Dehault A, Coopman S, Guimber D, Turck D, Gottrand F. One-step percutaneous gastrojejunostomy in early infancy. *J Pediatr Gastroenterol Nutr.* 2012;54:820-821.

11. Salinardi BJ, Harkin KR, Bulmer BJ, Roush JK. Comparison of complications of percutaneous endoscopic versus surgically placed gastrostomy tubes in 42 dogs and 52 cats. *J Am Anim Hosp Assoc.* 2006;42:51-56.
12. Armstrong PJ, Hardie EM. Percutaneous endoscopic gastrostomy: a retrospective study of 54 clinical cases in dogs and cats. *J Vet Intern Med.* 1990;4:202-206.
13. Ireland LM, Hohenhaus AE, Broussard JD, Weissman BL. A comparison of owner management and complications in 67 cats with esophagostomy and percutaneous endoscopic gastrostomy feeding tubes. *J Am Anim Hosp Assoc.* 2003;39:241-246.
14. Bright RM, DeNovo RC, Jones JB. Use of a low-profile gastrostomy device for administering nutrients in two dogs. *J Am Vet Med Assoc.* 1995;207:1184-1186.
15. Campbell SJ, Marks SL, Yoshimoto SK, Riel DL, Fascetti AJ. Complications and outcomes of one-step low-profile gastrostomy devices for long-term enteral feeding in dogs and cats. *J Am Anim Hosp Assoc.* 2006;42:197-206.
16. McCrackin Stevenson MA, Stiffler KS, Schmiedt CW. One-step placement of a percutaneous nonendoscopic low-profile gastrostomy port in cats. *J Am Vet Med Assoc.* 2000;217:1636-1641.
17. Breheny CR, Boag A, le Gal A, et al. Esophageal feeding tube placement and the associated complications in 248 cats. *J Vet Intern Med.* 2019;33:1306-1314.
18. Baker L, Beres AL, Baird R. A systematic review and meta-analysis of gastrostomy insertion techniques in children. *J Pediatr Surg.* 2015;50:718-725.
19. Michaud L, Guimber D, Blain-Stregloff AS, Ganga-Zandzou S, Gottrand F, Turck D. Longevity of balloon-stabilized skin-level gastrostomy device. *J Pediatr Gastroenterol Nutr.* 2004;38:426-429.
20. Ferguson DR, Harig JM, Kozarek RA, Kelsey PB, Picha GJ. Placement of a feeding button ("one-step button") as the initial procedure. *Am J Gastroenterol.* 1993;88:501-504.

How to cite this article: Craven MD. Repurposing medical devices as "button" esophagostomy tubes for extended nutritional support. *J Vet Intern Med.* 2022;36(1):196-203. doi:10.1111/jvim.16313